

# Microfoam Ultrasound-Guided Sclerotherapy Treatment for Varicose Veins in a Subgroup with Diameters at the Junction of 10 mm or Greater Compared with a Subgroup of Less Than 10 mm

JOHN M. BARRETT, FRNZCGP,<sup>1</sup> BRUCE ALLEN, FRACR,<sup>1</sup> ANNE OCKELFORD, FRNZCGP,<sup>1</sup> AND MITCHEL P. GOLDMAN, MD<sup>2</sup>

<sup>1</sup>*Palm Clinic, Auckland, New Zealand; and* <sup>2</sup>*Dermatology/Cosmetic Laser Associates of La Jolla, Inc., La Jolla, California*

**OBJECTIVE.** The objective was to analyze the effectiveness of foam ultrasound-guided sclerotherapy treatment in saphenous veins and tributary veins with a diameter at the saphenofemoral or saphenopopliteal junction of  $\geq 10$  mm and compare these results with a subgroup of veins with diameters of  $< 10$  mm.

**METHODS.** A subgroup of 17 saphenous veins with a diameter at the saphenofemoral or saphenopopliteal junction of  $\geq 10$  mm were compared with a subgroup of 98 saphenous veins with a diameter of  $< 10$  mm at the saphenofemoral or saphenopopliteal junction for clinical efficacy and patient satisfaction at a mean 2-year follow-up.

**RESULTS.** A mean number of 2.15 treatments utilizing an average of 8.37 mL of foam sclerosing solution (3% sodium tetradecyl sulfate) were required to close all incompetent varicose veins in the  $< 10$ -mm group versus a mean of 2.8 treatments and 13.9 mL foam (3% sodium tetradecyl sulfate) for the

$\geq 10$ -mm group. A total of 27.5% of saphenous veins of  $< 10$  mm and 37.5% of saphenous veins  $\geq 10$  mm required a second treatment at 3 months. One-hundred percent of patients believed that their legs were successfully treated at 2-year follow-up in both groups with 94% of the  $< 10$ -mm group noting improvements in quality of life and 100% in the  $\geq 10$ -mm group.

**CONCLUSIONS.** Ultrasound-guided foam sclerotherapy is effective in treating all sizes of varicose veins with high patient satisfaction and improvement in quality of life. Duplex ultrasound findings demonstrated a small increase in failure to close the saphenofemoral or saphenopopliteal junction with increasing size of junction diameter, but this does not significantly alter the results with respect to clearance of visible varicosities and patient satisfaction with results.

JOHN M. BARRETT, FRNZCGP, BRUCE ALLEN, FRACR, ANNE OCKELFORD, FRNZCGP, AND MITCHEL P. GOLDMAN, MD HAVE INDICATED NO SIGNIFICANT INTEREST WITH COMMERCIAL SUPPORTERS.

ULTRASOUND-GUIDED SCLEROTHERAPY has been previously thought to be useful only for saphenous veins where the diameter has been  $< 8$  mm.<sup>1</sup> It has been regarded that diameters of  $> 8$  mm have been the domain of surgery requiring ligation followed by stripping, sclerotherapy, or ambulatory phlebectomy. The assumption has been that sclerosants were not powerful enough to cause sufficient sclerosis in large vessels because of significant dilution of solutions by the blood volume in large-diameter veins. Foam sclerosants, however, allow maximum concentration of sclerosant at the surface of each microbubble, thus maximizing contact of the sclerosant at the endothelial

surface allowing more effective irritation and inflammation as precursors to sclerosis.<sup>2-8</sup>

The authors have used foam sclerotherapy with 3% sodium tetradecyl sulfate since September 2000 and in that period have treated more than 3000 legs. We have treated significant numbers of saphenous veins with diameters of  $\geq 10$  mm: 44 (10–14 mm), 31 (15–19 mm), and 7 ( $> 20$  mm). Our general experience suggested that there was equally high patient satisfaction in the larger vein patients but this required a study for confirmation of clinical efficacy.

## Materials and Method

Ninety-nine saphenous veins of  $< 10$ -mm junction diameter were analyzed retrospectively with a mean follow-up after treatment of 23.7 months (range, 19–29 months). These were compared with 17 saphenous

Address correspondence and reprint requests to: John M. Barrett, MD, Palm Clinic, 134 Remuera Road, Auckland, New Zealand, or e-mail: johnbarrett@palmclinic.co.nz.

veins of  $\geq 10$ -mm junction size with a mean follow-up after treatment of 24.5 months (range, 20–28 months).

Patients were asked to complete a quality-of-life and patient satisfaction survey and were reviewed clinically by Drs Barrett and Allen with visual assessment and duplex scanning.

Selection criteria for the study were:

1. Pretreatment truncal incompetence in primary greater saphenous or small saphenous veins as defined by reflux of  $> 0.5$  s documented by duplex/Doppler ultrasound scanning.
2. Tessari microfoam technique using 3% sodium tetradecyl sulfate in a ratio of 1 mL of sodium tetradecyl sulfate to 3 mL of ambient air for saphenous trunks and varying concentrations of microfoam polidocanol depending on the size of the saphenous branches and associated varicosities as described below. A concentration of 3% sodium tetradecyl sulfate was used for saphenous trunks because of its greater potency, and varying concentrations of polidocanol (1%–2.5%) were used for visible varicosities because in our experience this caused less phlebitis. (Lower concentrations of sodium tetradecyl sulfate would be equally suitable.)
3. Requiring to walk immediately after treatment for 30 min and then 1 hr per day. All legs were placed in Class 2, 30 to 40 mmHg graduated compression hosiery for a minimum of 2 weeks after treatment (1 week full-time and 1 week during the day only). Avoidance of straining and strenuous physical activity was required for the first 3 weeks (to avoid Valsalva maneuvers, which may contribute to early recanalization).
4. Avoid prolonged car or plane travel  $> 4$  hr for 1 month before and after treatment.
5. Treatment end point of closure of incompetent saphenous trunks, incompetent branch veins and all associated varicosities. Follow-up treatment was provided at 3 months if required.
6. Minimum of 1 year follow-up since treatment to enter study.

Typical protocols for our patients include:

- One leg: a treatment to the saphenous trunk (or trunks) typically involving four injections of 2 mL of foam 3% sodium tetradecyl sulfate with a repeat visit within 1 week to confirm closure of the saphenous trunk(s) and to treat the visible varicosities that were not already closed. Typically such follow-up treatments to visible varicosities involve lower concentrations of sclerosant, for example, 1% to 2.5% polidocanol. Perforators—particularly Cockett perforators—will often need additional

treatment at the second visit and this involves injecting at least 2 to 4 cm proximal or distal to the perforator with concentrations varying dependent on the size of the perforator.

- Two legs: the saphenous trunk(s) of one leg will be treated as above with the second leg being treated 2 days later and a third treatment to visible varicosities and/or distal perforators being completed 5 days later so that for the majority of patients the treatment of two legs is completed in three visits over 1 week with a follow-up at 3 months. We chose this protocol to minimize the time spent in compression hosiery.

Duplex guidance is mandatory for the nonvisible components of the treated veins.

## Results

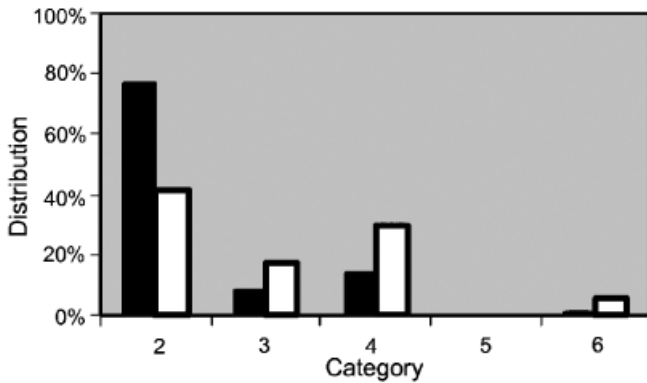
Results are shown in Table 1. Figure 1 shows the CEAP classifications.

The mean number of treatments required per leg including saphenous trunks, branches, and all visible varicosities was 2.15 for the  $< 10$ -mm group and 2.8 for the  $\geq 10$ -mm group. The mean total volume of 3% sodium tetradecyl sulfate foam used for completion of all treatments totaled 8.37 mL (range, 2–19 mL) for the  $< 10$ -mm group and 13.9 mL (range, 3–36 mL) for the  $\geq 10$ -mm group.

A total of 27.5% of the  $< 10$ -mm group and 37.5% of  $\geq 10$ -mm group required a second treatment at the 3 month follow-up (doses included in above totals). Such treatments were generally for a small channel in the saphenous trunk, for a small feeding vessel or perforator creating the channel, or for minor residual varicosities. The success of foam ultrasound-guided

**Table 1.** Comparative Data

Variable	Vein diameter	
	$< 10$ mm	$\geq 10$ mm
Sex		
Male (%)	31	37.5
Female (%)	69	62.5
Mean age (years)	52 (range 22–85)	50 (range 36–77)
Leg (%)		
Left	55	56
Right	45	44%
Number of veins		
Greater saphenous	79 (80%)	14 (82%)
Small saphenous	20	3
Both	11	1
Mean vein diameter (mm)	6.1	12
Mean follow-up (months)	23.7	24.5



**Figure 1.** Distribution by CEAP category. Class 1, reticular and spider veins (excluded from study); Class 2, varicose veins; Class 3, varicose veins with edema; Class 4, varicose veins with skin changes (e.g., lipodermatosclerosis/varicose, eczema/atrophie blanche); Class 5, varicose ulcers healed (none in study); Class 6, active varicose ulcers. (■) <10 mm; (□) ≥10 mm.

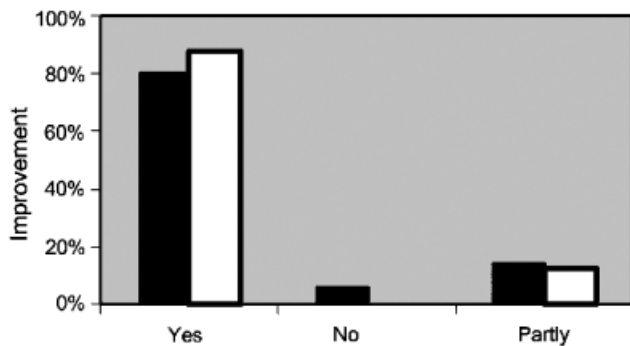
sclerotherapy was analyzed from two perspectives: patient satisfaction and clinical assessment.

*Patient Satisfaction*

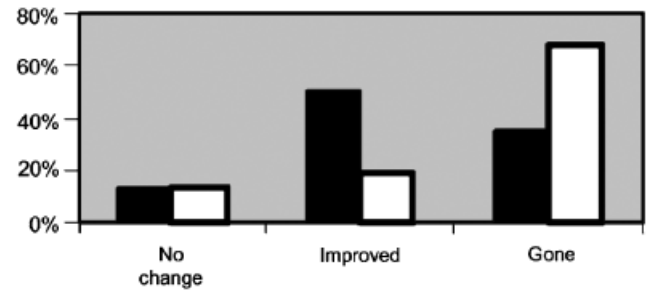
There was extremely high patient satisfaction in both groups. One-hundred percent of patients believed that foam ultrasound-guided sclerotherapy had been successful for treating their varicose veins and their related symptoms. Eighty-six percent registered complete success and 14% believed that foam ultrasound-guided sclerotherapy had been partly successful in the <10-mm group; 94% registered complete success and 6% part success in the ≥10-mm group. No one in either group rated his or her treatment as a failure.

*Quality-of-Life Questionnaire*

Ninety-four percent of patients in the <10-mm group believed that their quality of life had improved following treatment (80% complete and 14% partly). In the ≥10-mm group, 100% of patients believed their



**Figure 2.** Patient assessment of quality-of-life improvement after treatment. (■) <10 mm; (□) ≥10 mm.



**Figure 3.** Patient assessment of symptoms after treatment. (■) <10 mm; (□) ≥10 mm.

quality of life had improved (88% significantly and 12% partly) (see Figure 2). One-hundred percent of patients in both groups believed that the appearance of their legs had improved since treatment.

*Clinical Outcomes of Foam Ultrasound-Guided Sclerotherapy*

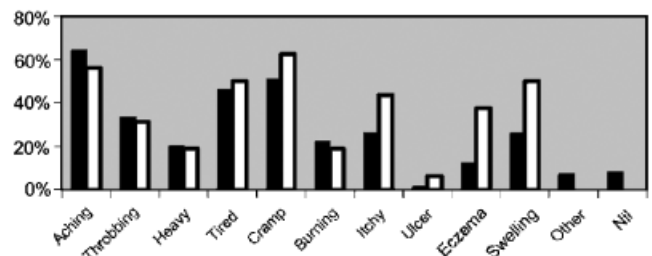
Ninety-two percent of legs in the <10-mm group and 94% in the ≥10-mm group had symptoms before treatment. The size of varicosities and degree of reflux were not accurate predictors of symptoms but there was an increased tendency for more severe symptoms in the ≥10-mm group.

After treatment, 86% of both groups showed improvement in symptoms (symptoms gone 35%, symptoms improved 51% for the <10-mm; symptoms gone 69%, symptoms improved 19% for the ≥10-mm group). Thirteen percent in both groups showed no change but the majority of the “no change” group (57%) did not have symptoms before treatment (see Figure 3).

Figure 4 demonstrates the percentage of patients with symptoms in each class before treatment. Symptoms in the “other” group included restless legs, heat, tenderness, bleeding, tingling, and superficial thrombophlebitis.

*Visible Varicosities*

Before treatment, the <10-mm group had 15% mild, 64% moderate, and 19% severe varicosities on visual



**Figure 4.** Symptoms by type before treatment. (■) <10 mm; (□) ≥10 mm.

assessment compared with 6% mild, 56% moderate, and 38% severe in the  $\geq 10$ -mm group

One-hundred percent of visible varicosities related to the treated saphenous veins were successfully treated clinically in both groups (92% completely removed, 8% significantly improved in the  $< 10$ -mm group; 94% completely removed, 6% significantly improved in the  $\geq 10$ -mm group). Four percent in the  $< 10$ -mm group and 6% in the  $\geq 10$ -mm group had developed new varicosities (generally minor) at 2-year follow-up related mostly to perforator incompetence.

### Duplex Scan Assessment

Mean follow-up interval was 23.7 months since first treatment (range, 19–29 months) for the  $< 10$ -mm group and 24.5 months (range, 20–28 months) for the  $\geq 10$ -mm group.

For the  $\geq 10$ -mm group, duplex scanning confirmed 88% successful treatment: 77% saphenous veins complete sclerosis and 21% with fibrosed vein ( $< 2$  to 3 mm and minimal flow) of the saphenous veins. Four percent of saphenous veins had reduced diameter but persistent reflux and would require further treatment if the varicosities returned. For the 10-mm group, duplex scanning confirmed 88% successful treatment: 69% with complete sclerosis and 19% with reduced diameter to  $< 2$  to 3 mm with minimal flow but an increase to 12% open at the junction (see Figure 5).

### Discussion

Despite the significant difference in mean diameters for the two groups studied (mean 6.1 mm and range 3–9 mm for the  $< 10$ -mm group; mean 12 mm and range 10–16 mm for the  $\geq 10$ -mm groups), on balance there were very few differences between the two groups.

As anticipated the  $\geq 10$ -mm group had more severe preclinical varicosities (CEAP classification and visible

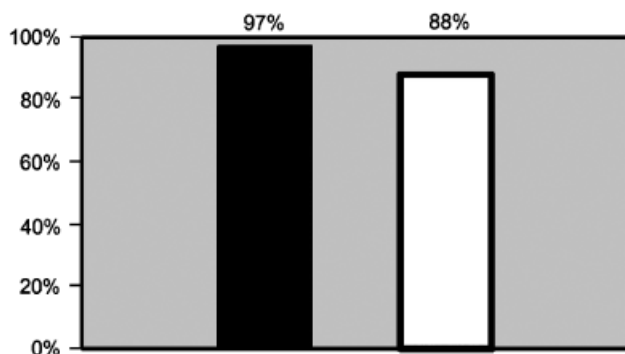
appearance) and associated symptoms. Interestingly the patient self-rating of satisfaction and quality-of-life issues showed a higher degree of satisfaction in the  $\geq 10$ -mm group, although ratings in both groups were very high. One assumes that patients with more severe symptoms are more impressed by improvement in those symptoms than patients with less severe symptoms who may be driven as much by desire for improved appearance.

The only significant difference was in the duplex findings: in the  $\geq 10$ -mm group there was a 12% incidence of failure to close the junction at 2-year follow-up compared with 4% for the  $< 10$ -mm group. This difference did not translate to objective visual recurrence (which demonstrated equally high resolution of the varicosities in both groups) or patient assessment of symptoms which showed an even greater improvement in the  $\geq 10$ -mm group. This supports other studies that have reported similar findings.<sup>1</sup>

Given that our protocol only involved follow-up treatment to 3 months (where required), it would not be unreasonable to assume that these already impressive results could be further improved by follow-up treatment if required at 1 year.

The technique has an exceptionally high safety profile with the protocol outlined in this and our previous study<sup>9</sup> in that we have had no serious adverse reactions in 3000 legs treated by foam ultrasound-guided sclerotherapy. Expected sequelae include blood trapping and hemosiderin staining in a significant proportion of patients and is typically proportional to the size of the vein. The former typically takes 3 to 6 months to resolve and can be associated with tenderness. The staining takes 6 to 12 months to resolve with rare cases of staining persisting beyond 1 year. Phlebitis due to excessive inflammation induced by the sclerosant occurs in  $< 5\%$  of patients. We have had no cases of major deep vein thrombosis or pulmonary embolism in more than 3000 legs treated and have documented six cases of minor deep vein thrombosis (five in medial gastrocnemius or soleus veins and one in a posterior tibial vein). The high relative safety combined with such high success rates and patient satisfaction makes foam ultrasound-guided sclerotherapy, in our opinion, a viable option to surgery for primary and secondary varicose veins regardless of size.

Surgery carries a significantly high rate of thromboembolism, nerve injury, and wound infection, plus small risks of general anesthesia.<sup>10–24</sup> Surgery is no more effective than foam ultrasound-guided sclerotherapy for primary truncal saphenous vein treatment and less so for recurrent varicose veins. It is difficult to justify a procedure that has increased patient morbidity (and mortality) and no significant increase in efficacy.



**Figure 5.** Trunk vein closed or competent after treatment. (■)  $< 10$  mm; (□)  $\geq 10$  mm.

Many surgeons are now turning to techniques for treating incompetent truncal varicose veins that no longer require general anesthesia, such as ambulatory phlebectomy, laser, or radiofrequency closure. None of these techniques can offer patients the simplicity of foam ultrasound-guided sclerotherapy because all require tumescent anesthesia. Ambulatory phlebectomy can only be used on tributary veins. Laser and radiofrequency closure can only be used on straight saphenous trunks, which form a minority of cases in our experience plus require ancillary treatment with ambulatory phlebectomy or sclerotherapy for the associated varicose veins.

Foam ultrasound-guided sclerotherapy is uniquely simple and relatively painless for the patient with high efficacy and patient satisfaction. It allows patients to return to work the same day, can be used for all age groups, is unaffected by common disease states that may preclude surgery (e.g., morbid obesity and heart disease), and has high patient safety.<sup>25</sup> Foam ultrasound-guided sclerotherapy is also very quick to perform (albeit needing repeat visits) without the high costs of newer endoluminal laser and radiofrequency ablation techniques.

## References

- Kanter A, Thibault P. Saphenofemoral incompetence treated by ultrasound guided sclerotherapy. *Dermatol Surg* 1996;22:648-52.
- Cabrera J, Cabrera J Jr, Garcia-Olmedo MA. Treatment of varicose long saphenous veins with sclerosant microfoam form: Long-term outcomes. *Phlebology* 2000;15:19-23.
- Cavezzi A, Frullini A. The role of sclerosing foam in ultrasound guided sclerotherapy of the saphenous veins and of recurrent varicose veins: our personal experience. *Aust N Z J Phlebol* 1999;3:49-50.
- Cavezzi A. The use of sclerosant foam in sclerotherapy: possibilities and limits. *Aust N Z J Phlebol* 2000;4:100-1.
- Tessari L, Cavezzi A, Frullini A. Preliminary experience with a new sclerosing foam in the treatment of varicose veins. *Dermatol Surg* 2001;27:58-60.
- Tessari L, Cavezzi A, Frullini A. New sclerosing foam. *Phlebol Digest* 2001;14:18-9.
- Frullini A, Cavezzi A. Sclerosing foam in the treatment of varicose veins and telangiectases: history and safety complications. *Dermatol Surg* 2002;28:11-5.
- Cavezzi A, Frullini A, Ricci S, Tessari L. Treatment of varicose veins by foam sclerotherapy: two clinical series. *Phlebology* 2002;17:13-8.
- Barrett JM, Allen B, Ockelford A, Goldman MP. Microfoam ultrasound guided sclerotherapy of varicose veins in 100 legs. *Dermatol Surg* 2004;30:6-12.
- Chant ADB, Jones HO, Weddell JM. Varicose veins: a comparison of surgery and injection/compression sclerotherapy. *Lancet* 1972;2:118-91.
- Beresford SA, Chant AD, Jones HO, Piachaud D, Weddell JM. Varicose veins. a comparison of surgery and injection/sclerotherapy: five-year follow-up. *Lancet* 1978;1:921-4.
- Doran FS, White M. A clinical trial designed to discover if the primary treatment of varicose veins should be Fegan's method or by an operation. *Br J Surg* 1975;62:72-6.
- Jakobsen B. The value of different forms of treatment for varicose veins. *Br J Surg* 1979;66:182-4.
- Hobbs JT. Surgery and sclerotherapy in the treatment of varicose veins. *Arch Surg* 1974;109:793-6.
- Hobbs JT. Surgery of sclerotherapy for varicose veins: 10-year results of a random study. In Tesi M, Dormandy J, eds. *Superficial and Deep Venous Disease of the Lower Limbs*. Turin: Edizione Minerva Medica, 1984:243-6.
- Einarsson E. Compression sclerotherapy of varicose veins. In Eklof B, Gjores JE, Thulesius O, Bergqvist D, eds. *Controversies in the Management of Venous Disorders*. London: Butterworth, 1989:203-11.
- Neglen P. Treatment of varicosities of saphenous origin: comparison of ligation, selective excision, and sclerotherapy. In Bergan JJ, Goldman MP, eds. *Varicose Veins and Telangiectasias: Diagnosis and Treatment*. St. Louis: Quality Medical Publishing, 1993:148-65.
- Liew SC, Huber D, Jeffs C. Day-only admission for varicose vein surgery. *Aust N Z J Surg* 1994;64:688-91.
- Hayden A, Holdsworth J. Complications following re-exploration of the groin for recurrent varicose veins. *Ann R Coll Surg Engl* 2001;83:272.
- Ramsheyl A, Soury P, Saliou C, et al. Inadvertent arterial injury during saphenous vein stripping: three cases and therapeutic strategies. *Arch Surg* 1998;133:1120-3.
- Wellwood JM, Cox SJ, Martin A, et al. Sensory changes following stripping of the long saphenous vein. *J Cardiovasc Surg* 1975;16:123-4.
- Docherty JG, Morrice JJ, Bell G. Saphenous neuritis following varicose vein surgery. *Br J Surg* 1974;1:415-7.
- Holme JB, Skajaa K, Holme K. Incidence of lesions of the saphenous nerve after partial or complete stripping of the long saphenous vein. *Acta Chir Scand* 1990;156:145-8.
- Bounameaux H, Huber O. Postoperative deep vein thrombosis and surgery for varicose veins. *BMJ* 1996;312:116.
- Varcoe PF. Duplex-guided sclerotherapy: the international survey. *Aust N Z J Phlebol* 2004;in press.